

# Prelacrimal window approach to the maxillary sinus: a systematic review and meta-analysis of the literature\*

André Machado<sup>1,2,†</sup>, Joana Pereira<sup>2,†</sup>, Francisco Alvarez<sup>2</sup>, Hans Rudolf Briner<sup>3</sup>,  
Daniel Simmen<sup>3</sup>

**Rhinology** 62: 3, 0 - 0, 2024

<https://doi.org/10.4193/Rhin23.296>

<sup>1</sup> Department of Otolaryngology, Centro Hospitalar Universitário de Santo António, Porto, Portugal

<sup>2</sup> Faculdade de Ciências da Saúde, Universidade da Beira Interior, Covilha, Portugal

<sup>3</sup> ORL-Zentrum, Hirslanden Klinik, Zurich, Switzerland

**\*Received for publication:**

September 20, 2023

**Accepted:** January 28, 2024

# contributed equally

## Abstract

**Background:** The prelacrimal window approach (PLWA) is a minimally invasive surgical technique that has been proposed as an alternative to the traditional approaches to access the maxillary sinus.

**Methodology:** A systematic review with meta-analysis was performed following PRISMA guidelines and identified 368 articles for initial review of which 14 (610 participants) met the criteria for meta-analysis. Four databases, including PubMed, Google Scholar, Web of Science and Scopus, were searched to identify relevant articles. Two independent reviewers conducted the eligibility assessment for the included studies. Methodology quality and risk of bias were evaluated by New Castle Ottawa scale. The outcomes assessed were recurrence of the pathology, postoperative morbidity including epiphora, dry nose, facial, gingival numbness, epistaxis or local infection.

**Results:** The present data suggest a significant reduction in the recurrence rate of maxillary sinus pathology following PLWA when compared to conventional surgery (endoscopic medial maxillectomy, endoscopic sinus surgery and the Caldwell–Luc operation). The rates of epiphora, facial or gingival numbness, epistaxis or infection requiring intervention, were not significantly different between the procedures.

**Conclusions:** Maxillary sinus pathology can be effectively treated using the PLWA technique, as it has been shown to result in a lower recurrence rate compared to conventional surgeries.

**Key words:** maxillary sinus, prelacrimal approach, endoscopic sinus surgery, prelacrimal recess, lateral nasal wall, sinusitis

## Introduction

The maxillary sinus (MS) is the largest among the paranasal sinuses <sup>(1,2)</sup> and is commonly affected by a wide range of diseases including benign and malignant neoplasms, infections, chronic inflammation and lesions with odontogenic origin <sup>(3)</sup>.

Historically, the Caldwell–Luc (CL) approach was one of the first proposed techniques to access the MS and was originally described by George Caldwell in 1893 <sup>(4)</sup>. Despite providing better access to the MS, external approaches like CL approach are associated with an increased risk of surgery-related morbidities such as facial swelling and facial and dental numbness <sup>(4,5)</sup>.

Besides these morbidities, the CL approach does not always

provide adequate access to particular areas of the MS <sup>(5)</sup>, especially the prelacrimal recess and the alveolar recess <sup>(6)</sup> when a Mini CL procedure is performed. Therefore, with the development of advanced endoscopes, the CL approach is considered a final recourse in surgical treatment when other surgical techniques are proven ineffective in managing MS pathology <sup>(7,8)</sup>.

Consequently, in the past few years, due to important technological developments, the use of endoscopic surgery has substantially grown and it is now considered the standard procedure for the surgery of most MS diseases <sup>(9)</sup>. Approaches including endoscopic sinus surgery (ESS), particularly middle meatus antrostomy, occasionally augmented by inferior meatus antrostomy <sup>(10-12)</sup>,

and endoscopic medial maxillectomy (EMM) are being used. However, these have some limitations. Despite the development of new endoscopes and considering the unique anatomy features, there are still some areas difficult to reach, particularly the anterior and the inferior walls of the MS and the prelacrimal recess (PLR) <sup>(8, 13)</sup>. An ostium opening, as performed in ESS, might not be sufficient to access these areas <sup>(14)</sup>. Furthermore, in EMM the inferior turbinate (IT) and the nasolacrimal duct (NLD) are typically sacrificed, occasionally leading to functional problems <sup>(9)</sup>. To overcome these limitations, a prelacrimal window approach (PLWA) via the prelacrimal recess, initially reported by Zhou et al. in 2007 <sup>(15, 16)</sup>, was developed as an alternative surgery to access the MS. This technique begins with an incision along the superior edge of the inferior turbinate, extending inferiorly until reaching the anterior head <sup>(13)</sup>. Following this, the mucoperiosteum is elevated and reflected down to expose the inferior turbinate bone and the ridge of the piriform aperture where the osteotomies will be performed <sup>(13)</sup>. After the bone removal, the mucosa of the maxillary sinus anterior to the nasolacrimal duct is exposed and the nasolacrimal duct is retracted, ensuring a broad access to the maxillary sinus while preserving the nasolacrimal duct <sup>(13)</sup>. Lastly, the mucosa and the inferior turbinate are carefully repositioned, restoring them to their initial anatomical locations, thereby allowing the preservation of the nasal anatomy <sup>(9, 13)</sup>. Subsequently, the incision is sutured, ensuring a secure and precise closure <sup>(13)</sup>. Figure 1 illustrates the PLWA. Due to MS anatomical characteristics, the PLWA is particularly important in treating pathologies affecting the anterior and inferior walls of the sinus and also the prelacrimal recess, as they can be challenging to access using conventional techniques, even for experienced surgeons <sup>(13, 17, 18)</sup>.

Previous research also supports both the safety and feasibility of the PLWA particularly in the management of inverted papilloma <sup>(19)</sup>, although there are few studies demonstrating if PLWA is better than conventional surgery in treating other MS diseases. The aim of this systematic-review and meta-analysis was to evaluate the efficacy and safety of the PLWA in managing different MS pathologies, as well as compare the outcomes between the PLWA and conventional surgery.

## Materials and methods

A systematic review with meta-analysis was performed following the Preferred Reporting Items for Systematic Reviews and Meta-Analyses (PRISMA) guidelines <sup>(20)</sup>.

## Eligibility criteria

In this review, studies were included in the analysis if they fulfilled the following criteria: 1) studies: cohort studies, case-control and clinical trials, retrospective or prospective; 2) population: patients diagnosed with maxillary sinus pathology without any limitations on sex, nationality or race; 3) intervention: endo-

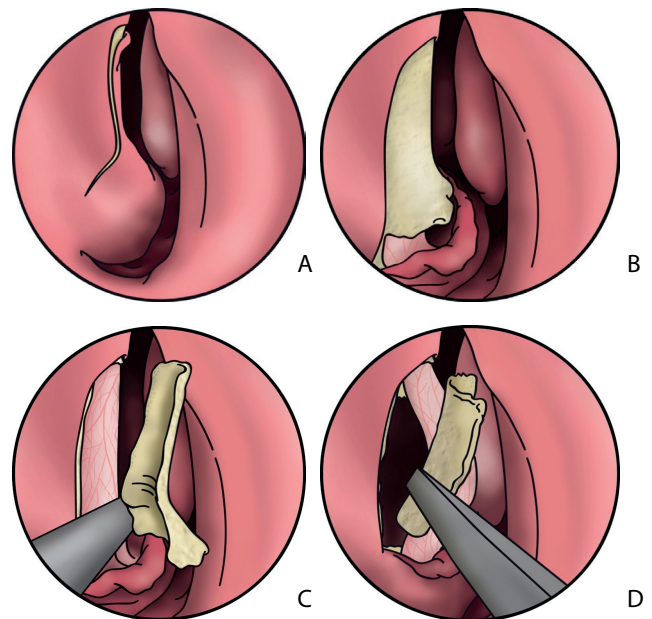


Figure 1. Prelacrimal Window Approach. Legend – A) Incision on the mucosa, anterior to the nasolacrimal duct; B, C) Chisel used to remove the bone over the lacrimal duct; D) After freeing the bone medial to the lacrimal duct with a chisel, this segment is removed. Pictures from Simmen D, Jones N. *Manual of endoscopic sinus and skull base surgery*. Second edition. ed. Stuttgart: Thieme; 2014.

scopic sinus surgery by prelacrimal window approach (PLWA); 4) comparison: conventional surgery (EMM, ESS) and/or the CL approach; 5) outcomes: at least one of the following: recurrence rate, postoperative morbidities such as epiphora, dry nose, facial or gingival numbness and epistaxis or post-operative infection requiring intervention. PICO framework <sup>(21)</sup> was used as a basis for establishing these criteria. Only human studies and articles with full text access were included. For studies in which the full text was not available the authors were contacted. Studies were excluded from the analysis if they met following criteria: 1) letters to editor, case reports and reviews; 2) language other than English, Dutch, French, Spanish, Italian or Portuguese. No exclusion criteria based on the publication date was applied.

## Information sources and search strategy

Four databases, including PubMed, Google Scholar, Web of Science and Scopus, were searched to identify relevant articles with the last survey conducted on March 28th, 2023. The search was performed using the queries available in Table 1. This phase had no limitations regarding time or language.

## Study selection process

After duplicates were removed, two authors (AM and JP) independently screened all titles and abstracts according to the eligibility criteria. After the initial screening, the full text of selected articles was then evaluated. Any disagreement between authors

Table 1. Literature search queries.

Databases	Queries	Searched results
MEDLINE (PubMed) and Google Scholar	("prelacrimal"[All Fields] AND ("approach"[All Fields] OR "approach s"[All Fields] OR "approachability"[All Fields] OR "approachable"[All Fields] OR "approche"[All Fields] OR "approached"[All Fields] OR "approaches"[All Fields] OR "approaching"[All Fields] OR "approachs"[All Fields]))	83
Web of Science	(ALL= ("prelacrimal")) AND (ALL = ("approach" OR "approach s" OR "approachability" OR "approachable" OR "approche" OR "approached" OR "approaches" OR "approaching" OR "approachs"))	71
Scopus	ALL ("prelacrimal") AND ("approach" OR "approach s" OR "approachability" OR "approachable" OR "approche" OR "approached" OR "approaches" OR "approaching" OR "approachs")	214

was discussed and solved by consensus.

### Data extraction

The data and study details were extracted manually by two independent reviewers (AM and JP). A pre-defined form was used to obtain the following information from each study: first author, publication year, continent, country, study design, total number of patients, age of patients, gender of patients, number of patients for each intervention, pathology, attachment sites in MS, follow-up time and incidence of each outcome of interest (recurrence and/or postoperative morbidities). In case of disagreement, the resolution was achieved through consensus.

### Risk of bias in included studies

Risk of bias of each study was assessed using the Newcastle-Ottawa Scale <sup>(22)</sup>. This assessment was independently performed by the same two authors. Disagreements were solved by consensus.

### Data synthesis and statistical analysis

The following outcomes were selected to be included in the meta-analysis: recurrence and postoperative morbidities such as epiphora, dry nose, and epistaxis or infection requiring intervention. Facial or gingival numbness was also assessed as separated. To perform the data analysis two statistical programs were used. A proportional meta-analysis was carried out using software R (metafor package) to analyze studies that assessed the effects of PLWA. Forest plots were constructed to illustrate the results and results were expressed as a proportion with their corresponding 95% confidence intervals (95% CIs). An analysis with software Review Manager 5.4 [The Cochrane Collaboration, 2020] was also performed to compare the effects of the PLWA with conventional surgery (EMM, ESS, and/or CL). Odds ratio (OR) was calculated as a measure of effect for the analysis of dichotomous variables with a 95% CI. Statistical analysis was performed using a random-effects model. The treatment outcomes were also provided in the form of a forest plot. Heterogeneity between studies was assessed using Cochran's Q test and  $I^2$  statistic. A p-value <0.10 and/or  $I^2$  >40% were considered to represent substantial heterogeneity. A p-value of < 0.05 was interpreted as

statistically significant. Heterogeneity was investigated by performing subgroup analyses for each outcome. Funnel plots were created to assess publication bias using the Metafor package in the R program.

## Results

### Study selection

A comprehensive search of the literature identified 368 articles for initial review from PubMed, Google Scholar, Web of Science and Scopus databases. 224 articles were identified and screened by title and abstract after exclusion of duplicates. Following this, 25 articles underwent full-text assessment. Of those, 14 met criteria for meta-analysis <sup>(10-12, 16, 23-32)</sup>. Figure 2 shows the PRISMA flow diagram of the study selection process.

### Study characteristics

Table 2 describes the main characteristics of each study.

14 articles (13 retrospective and 1 prospective) were included in the systematic review. Four of the studies were conducted in China, one in Turkey, two in Taiwan, two in Germany, one in France, two in South Korea, one in India and one in Australia, representing three different continents. Follow-up time ranged from 7 to 134 months and included data from 2013 to 2022. The selected studies involved a total of 610 participants. The age of the patients was only mentioned in eleven studies <sup>(10, 12, 23, 25-32)</sup> with a range of 14 to 76 years. Of the remaining three studies, one <sup>(11)</sup> reported that 23 patients were aged 20 to 30 years and two <sup>(16, 24)</sup> had no data regarding age. Ten studies provided information on the gender of the patients with a total of 301 male and 183 female. The diagnoses, postoperative morbidities and recurrence rates of each study are represented in Table 2. Among included studies, two compared PLWA with EMM <sup>(24, 32)</sup> one compared PLWA with CL <sup>(28)</sup>, one compared PLWA with ESS <sup>(11)</sup> and two compared PLWA with EMM, ESS, and CL <sup>(19, 44)</sup>. Eight studies assessed only PLWA <sup>(16, 23, 25-27, 29-31)</sup>.

### Risk of bias in the included studies

Table 3 summarizes the risk of bias of the selected articles. The Newcastle-Ottawa Scale ranges from 0 to 9 points with higher scores indicating a higher quality of the studies. The

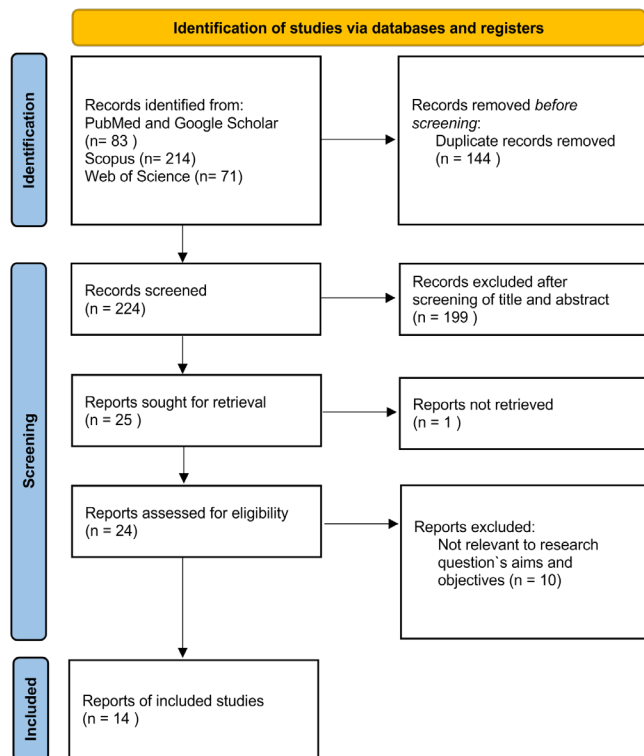


Figure 2. PRISMA flow diagram.

median score of included studies was 6.9.

Figure 3 and 4 displays funnel plots relating to publication bias. Visual inspection does not show evidence of publication bias when comparing the PLWA with conventional surgery (Figure 4). Due the limited number of studies included in the meta-analysis; it was not possible to conduct funnel plot analyses for the other outcomes.

### Comparison of the PLWA and conventional surgery

#### Recurrence rate

Six studies <sup>(11, 12, 19, 24, 28, 32)</sup> reported data regarding maxillary sinus pathology recurrence, with 188 patients in the PLWA group and 280 in the conventional surgery group (EMM, ESS and CL). The results showed a significant reduction in the recurrence rate of maxillary sinus pathology following PLWA when compared to conventional surgery ([OR]=0.28; 95% CI: 0.10, 0.79;  $p=0.02$ ;  $I^2=0\%$ ) (Figure 5).

#### Postoperative morbidities

Among the included studies, four <sup>(11, 12, 28, 32)</sup> reported information on postoperative morbidities. The rate of dry nose ([OR]=0.10; 95% CI: 0.01, 1.07;  $p=0.06$ ;  $I^2=36\%$ ) and epiphora ([OR]=0.54; 95% CI: 0.03, 9.74;  $p=0.68$ ;  $I^2=69\%$ ) were not significantly different between the procedures, and substantial heterogeneity was observed for epiphora (Figures 6 and 7). Regarding epistaxis/infection requiring intervention ([OR]=0.20; 95% CI: 0.04, 1.00;  $p=0.05$ ;  $I^2=0\%$ ), the test for overall morbidities sug-

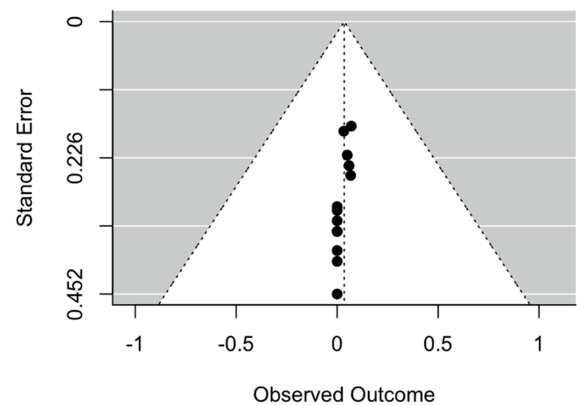


Figure 3. Funnel plots of publication bias assessment for the recurrence outcome studies. Global recurrence rate – observed outcome. Legend: Pre-Lacrimal Window Approach (PLWA).

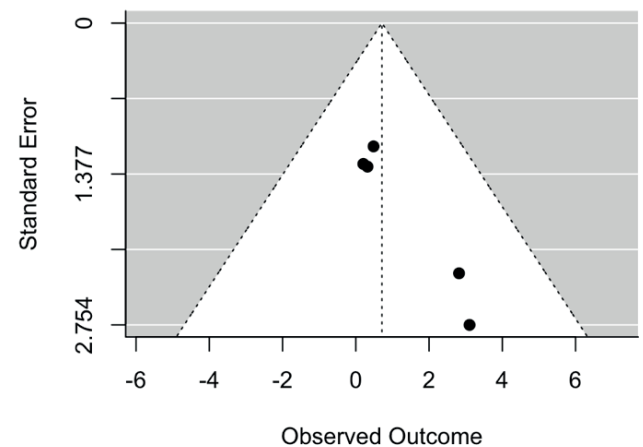


Figure 4. Funnel plots of publication bias assessment for the recurrence outcome studies. Odds ratios for maxillary sinus pathology recurrence comparing the PLWA with conventional surgery – observed outcome. Legend: Pre-Lacrimal Window Approach (PLWA).

gested a trend towards statistical significance, however it did not reach conventional levels of significance ( $p < 0.05$ ) (Figure 8). Additionally, the rate of facial or gingival numbness ([OR]=0.68; 95% CI: 0.28, 1.67;  $p=0.40$ ;  $I^2=0\%$ ) was not significantly different between the assessed surgical techniques (Figure 9).

### PLWA

#### Recurrence rate and postoperative morbidities

Based on the data from all included studies, the meta-analysis revealed recurrence rates of 1.50% (95% CI: 0.10, 3.90;  $I^2=0\%$ ) for maxillary sinus pathology, and rates of 0.56% (95% CI: 0.00, 3.36;  $I^2=0\%$ ), 0.32% (95% CI: 0.00, 4.89;  $I^2=0\%$ ), 0.63% (95% CI: 0.00, 3.96;  $I^2=0\%$ ) and 12.11% (95% CI: 4.23, 22.55;  $I^2=74\%$ ) for epiphora, dry nose, epistaxis or infection requiring intervention and facial or gingival numbness, respectively (Figures 10, 11, 12, 13 and 14).

Table 2. Study characteristics of the included studies.

Study (design)	Continent (Country)	Group [PLWA (n)/Comparison (n)]	Age, median (range) or mean (SD), y	Number of patients (M/F)	Follow up, median (range) or mean (SD), m	Pathology	Attachment sites in MS	Outcome	Complication	Recurrence
Zhou 2013 <sup>(16)</sup> (Retrospective cohort)	Asia (China)	PLWA (17)	NA	17 (NA)	7 - 60	Inverted papilloma - 10 Nasal polyps - 2 Kubo's postoperative cyst of MS - 2 Recurrent bone cyst of maxilla - 1 Dentigerous cyst - 1 Bleeding of internal maxillary artery secondary to Caldwell-Luc operation - 1	NA	Incidence (recurrence, complication)	Epiphora (PLWA - 0) Dry nose (PLWA - 0) Numbness (PLWA - 0)	PLWA - 1
Comoglu 2016 <sup>(23)</sup> (Retrospective cohort)	Asia (Turkey)	PLWA (12)	22 (14-31)	12 (7/5)	14.2 (8-21)	Antrchoanal polyp - 12	A, M - 2 A, L - 4 L - 3 P - 2	Incidence (recurrence, complication)	Epiphora (PLWA - 0)	PLWA - 0
Jiang 2017 <sup>(24)</sup> (Retrospective cohort)	Asia (China)	PLWA (6) / EMM (16)	NA	22 (NA)	60 (24-120)	Inverted papilloma - 22	NA	Comparison (recurrence, complication) Incidence (recurrence, complication)	Epiphora (PLWA - 0) Dry nose (PLWA - 0) Numbness (PLWA - 0)	PLWA - 0 EMM - 0
Yu 2018 <sup>(12)</sup> (Retrospective cohort)	Asia (China)	PLWA (20) / ESS+CL (7), EMM (30), ESS (14)	52 (25-76)	71 (44/27)	37-73	Inverted papilloma - 71	PLWA: I, M - 3 A - 2 M - 1 A, M - 5 M, L, I - 1 M, P - 1 M, A, I - 3 Diffuse - 2 L, I - 1 P, I - 1 ESS: P, L - 14 CL: A, M, I - 7	Comparison (recurrence, complication) Incidence (recurrence, complication) Numbness (PLWA - 0); ESS+CL - 1; EMM - 0; ESS - 0 Epistaxis (PLWA - 0; ESS+CL - 0; EMM - 1; ESS - 1)	Epiphora (PLWA - 0; ESS+CL - 0; EMM - 1; ESS - 0) Dry nose (PLWA - 0; ESS+CL - 0; EMM - 1; ESS - 0) Numbness (PLWA - 0; ESS+CL - 1; EMM - 0; ESS - 0)	PLWA - 1 ESS+CL - 1 EMM - 2 ESS - 2
Zhou 2018 <sup>(25)</sup> (Retrospective cohort)	Asia (China)	PLWA (71)	52.18 (12.09)	71 (42/29)	37.3 (13-134)	Inverted papilloma - 71	NA	Incidence (recurrence, complication)	Numbness (PLWA - 11)	PLWA - 5

Table continues on next page

Table 2 continued. Study characteristics of the included studies.

Study (design)	Continent (Country)	Group (PLWA (n)/ Comparison (n))	Age, median (range) or mean (SD), y	Number of patients (M/F)	Follow up, median (range) or mean (SD), m	Pathology	Attachment sites in MS	Outcome	Complication	Recurrence
Lin 2018 <sup>(26)</sup> (Retrospective cohort)	Asia (Taiwan)	PLWA (15)	49.5±15.3	15 (12/3)	16.5 (6-28)	Inverted papilloma - 9 Necrotizing inflammation - 1 Inflammatory pseudotumor-like lesion - 1 Olfactory neuroblastoma - 1 Angioleiomyoma - 1 Chronic inflammation - 2	Inverted papilloma: PLR - 2 A - 1 L - 2 P - 3 I, L - 1	Incidence (recurrence, complication)	Numbness (PLWA - 0)	PLWA - 1
Hildenbrand 2019 <sup>(27)</sup> (Retrospective cohort)	Europe (Germany)	PLWA (17)	54.3	17 (13/4)	45.9 (24-69)	Inverted papilloma - 17	NA	Incidence (recurrence, complication)	Numbness (PLWA - 4)	PLWA - 0
Lee 2019 <sup>(28)</sup> (Retrospective cohort)	Asia (South Korea)	PLWA (10) / ESS+CL (30)	53.3 (13.3)	40 (32/8)	12.4 ± 11.7	Inverted papilloma - 38 Ameloblastoma - 1 Ossifying fibroma - 1	A - PLWA: 3; CL: 8 P - CL: 2 L - PLWA: 1; CL: 2 M - PLWA: 2; CL: 6 S - CL: 5 I - PLWA: 1; CL: 4 Diffuse - PLWA: 3; CL: 3	Comparison (recurrence, complication) Incidence (recurrence, complication)	Epiphora (PLWA - 0) Numbness (PLWA - 3 / ESS+CL - 11) Epistaxis (PLWA - 0 / ESS+CL - 0)	PLWA - 0 ESS+CL - 0
Giotakis 2019 <sup>(29)</sup> (Retrospective cohort)	Europe (Germany)	PLWA (17)	56.5	17 (NA)	31.3 (12-54)	Inverted papilloma - 17	NA	Incidence (recurrence, complication)	Epiphora (PLWA - 0) Numbness (PLWA - 5)	PLWA - 0
Lin 2020 <sup>(30)</sup> (Retrospective cohort)	Asia (Taiwan)	PLWA (21)	51.7 (14.5)	21 (16/5)	12.7 (1.4-41.5)	Sinonasal papilloma - 9 Primary chronic rhinosinusitis - 2 Recurrent bilateral CRS with nasal polyps - 1 Sinonasal organized hematoma - 1 Cavernous hemangioma - 1 Odontogenic cysts - 3 Trauma-related disorders - 2 Individual malignancies - 2	Sinonasal papilloma: M, P - 2 M, A, L - 1 P, L - 1 I, M - 1 A, I - 1 A - 1 Diffuse - 1 A, L, P - 1	Incidence (recurrence, complication)	Numbness (PLWA - 11) Epistaxis (PLWA - 1)	PLWA - 0

Table continues on next page

Table 2 continued. Study characteristics of the included studies.

Study (design)	Continent (Country)	Group [PLWA (n)]/ Comparison (n]	Age, median (range) or mean (SD), y	Number of patients (M/F)	Follow up, median (range) or mean (SD), m	Pathology	Attachment sites in MS	Outcome	Complication	Recurrence
Mohankumar 2021 <sup>(11)</sup> (Prospective cohort)	Asia (India)	PLWA (30) / ESS (30)	23 patients 20-30y	60 (NA)	12	Maxillary sinusitis – 24 Allergic fungal rhino sinusitis – 8 Antrochoanal polyp – 24 Dentigerous cyst – 4	Antrochoanal polyp: A - PLWA: 4; ESS: 3 P - PLWA: 1; ESS: 3 L - PLWA: 1; ESS: 1 M - PLWA: 2; ESS: 2 I - PLWA: 4; ESS: 3	Comparison (recurrence, complication) Incidence (recurrence, complication)	Epiphora (PLWA - 3; ESS - 0) Numbness (PLWA - 1; ESS - 0)	PLWA - 1 EMMA - 6
Seresirichorn 2022 <sup>(31)</sup> (Retrospective cohort)	Oceania (Australia)	PLWA (40)	52.8 (17)	40 (15/25)	50.1 (25.2)	Pyriform aperture stenosis – 2 Antrochoanal polyp – 2 Mucocoele – 1 Fungal ball – 4 Odontogenic maxillary sinusitis – 2 Allergic fungal rhinosinusitis – 2 Chronic rhinosinusitis – 4 Odontogenic neoplasms – 6 Paranasal neoplasm – 10 Skull base neoplasms – 4	NA	Incidence (complication)	Epiphora (PLWA - 0) Numbness (PLWA - 5) Epistaxis/ infection requiring intervention (PLWA - 0)	
Kim 2022 <sup>(10)</sup> (Retrospective cohort)	Asia (South Korea)	PLWA or EMM (28) / ESS+CL, ESS (127)	55.9	155 (101/54)	24.2	Inverted papilloma - 155	NA	Comparison (recurrence) Incidence (recurrence)		ExPA (PLWA or EMM) - 0 ESS+CL - 2 ESS - 7
Vinciguerra 2022 <sup>(32)</sup> (Retrospective cohort)	Europe (France)	PLWA (26) / EMM (26)	PLWA - 57.5 (11.19) EMM - 57.7 (14.4)	52 (29/23)	PLWA - 21.3 (12.1) EMM - 37.7 (15.6)	Inverted papilloma - 52	A - PLWA: 5; EMM: 6 L - PLWA: 7; EMM: 5 P - PLWA: 3; EMM: 4 M - PLWA: 2; EMM: 5 I - PLWA: 2; EMM: 1 S - PLWA: 6; EMM: 1 Diffuse: PLWA: 1; EMM: 4	Comparison (recurrence, complication) Incidence (recurrence, complication)	Epiphora (PLWA - 1; EMM - 10) Dry nose (PLWA - 1; EMM - 13) Numbness (PLWA - 6; EMM - 8) Epistaxis/infection requiring intervention (PLWA - 1; EMM - 6)	PLWA - 0 EMM - 1

Legend: Pre-Lacrimal Window Approach (PLWA), Endoscopic Sinus Surgery (ESS), Caldwell-Luc (CL) approach, Endoscopic Medial Maxillectomy (EMM), Not Available (NA), Anterior (A) wall, Lateral (L) wall, Posterior (P) wall, Medial (M) wall, Inferior (I) wall, Superior (S) wall, Prelacrimal recess (PLR), Maxillary sinus (MS).

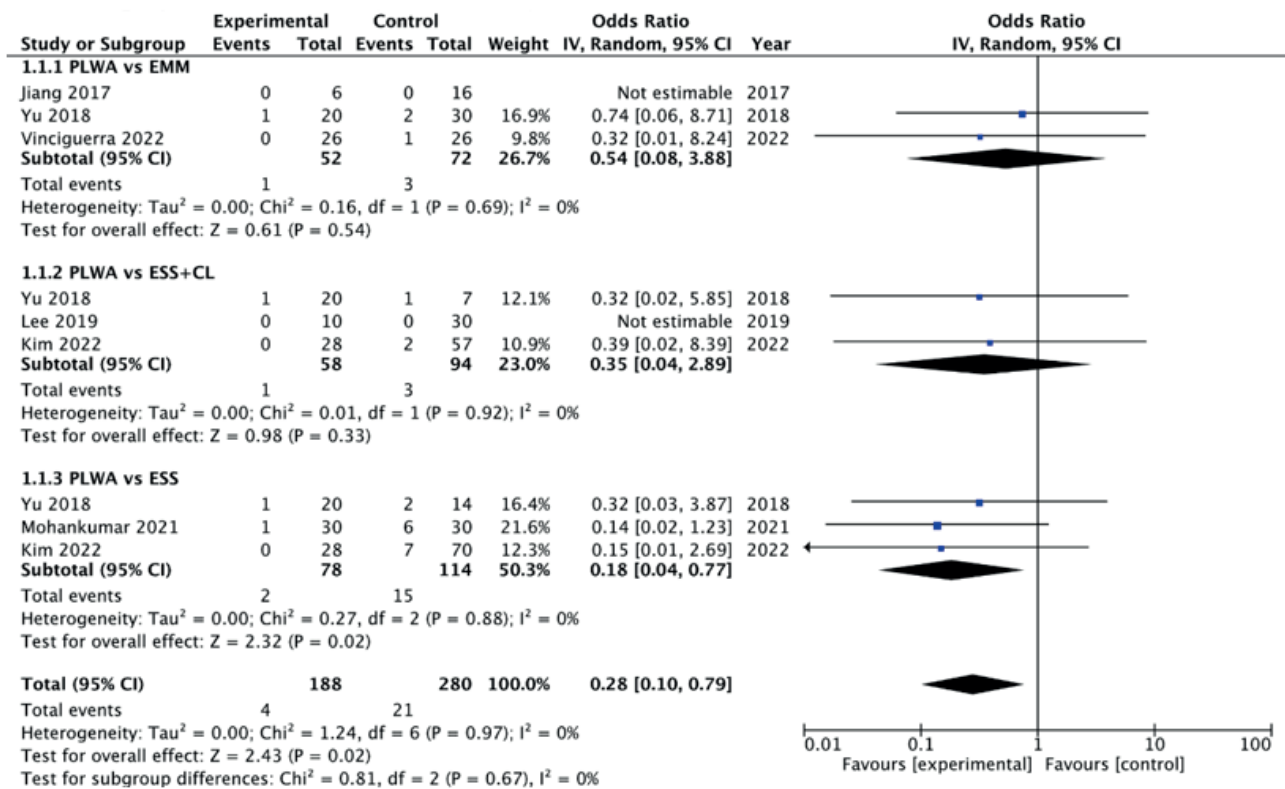


Figure 5. Comparison of the PLWA and conventional surgery on recurrence rates of maxillary sinus pathologies. Legend: Pre-Lacrimal Window Approach (PLWA), Endoscopic Sinus Surgery (ESS), Endoscopic Medial Maxillectomy (EMM), Caldwell–Luc (CL) approach, Confidence Interval (CI).

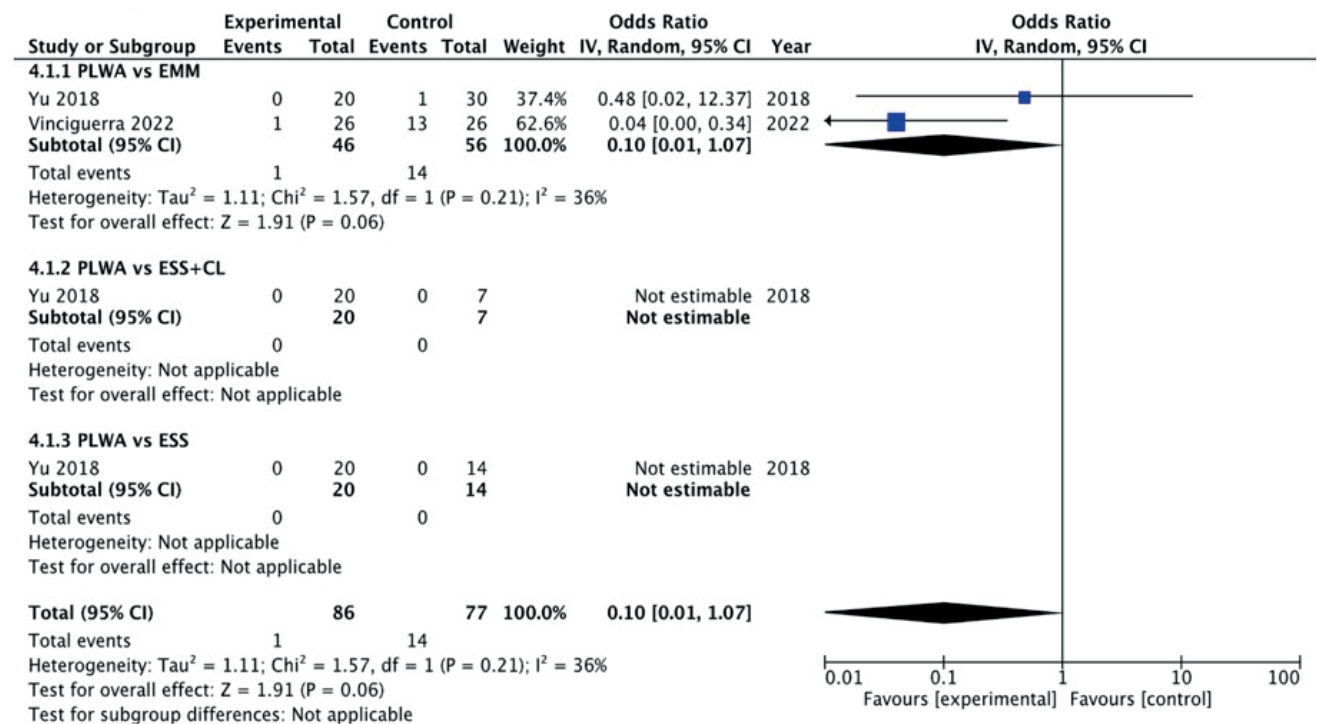


Figure 6. Comparison of the PLWA and conventional surgery on dry nose. Legend: Pre-Lacrimal Window Approach (PLWA), Endoscopic Sinus Surgery (ESS), Endoscopic Medial Maxillectomy (EMM), Caldwell–Luc (CL) approach, Confidence Interval (CI).

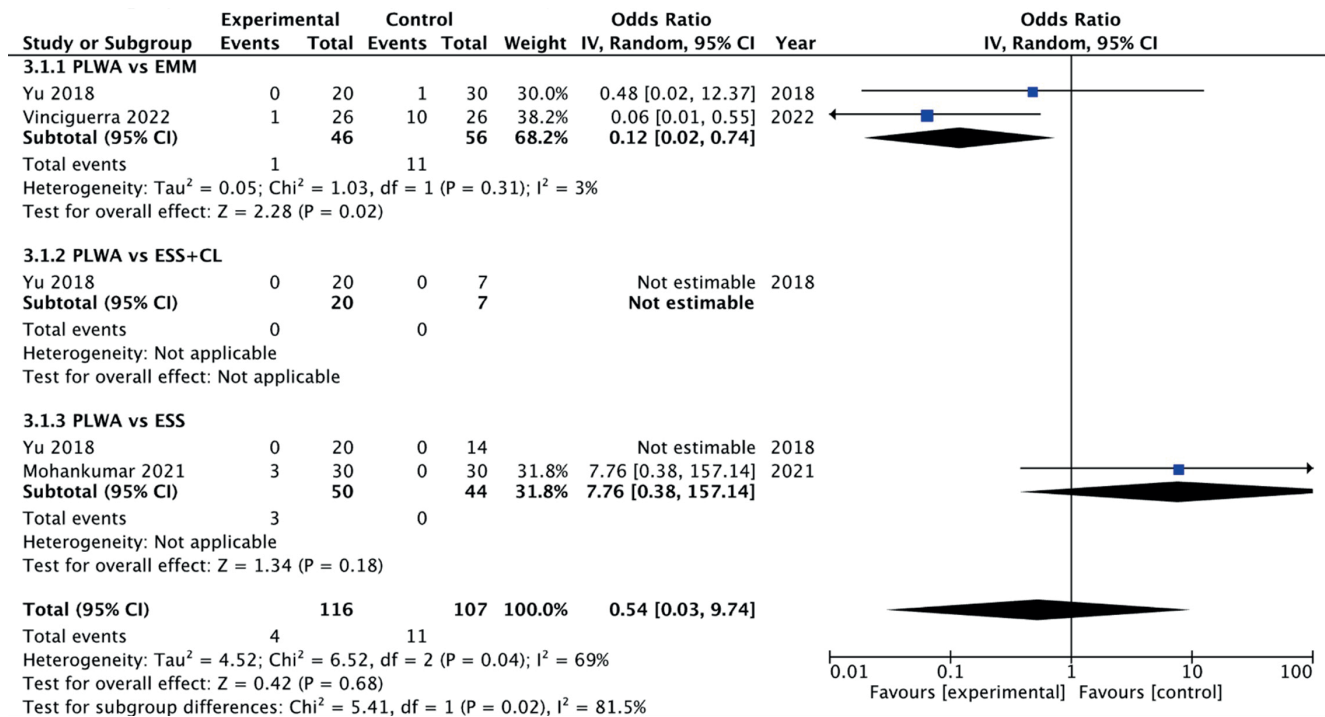


Figure 7. Comparison of the PLWA and conventional surgery on epiphora. Legend: Pre-Lacrimal Window Approach (PLWA), Endoscopic Sinus Surgery (ESS), Endoscopic Medial Maxillectomy (EMM), Caldwell–Luc (CL) approach, Confidence Interval (CI).

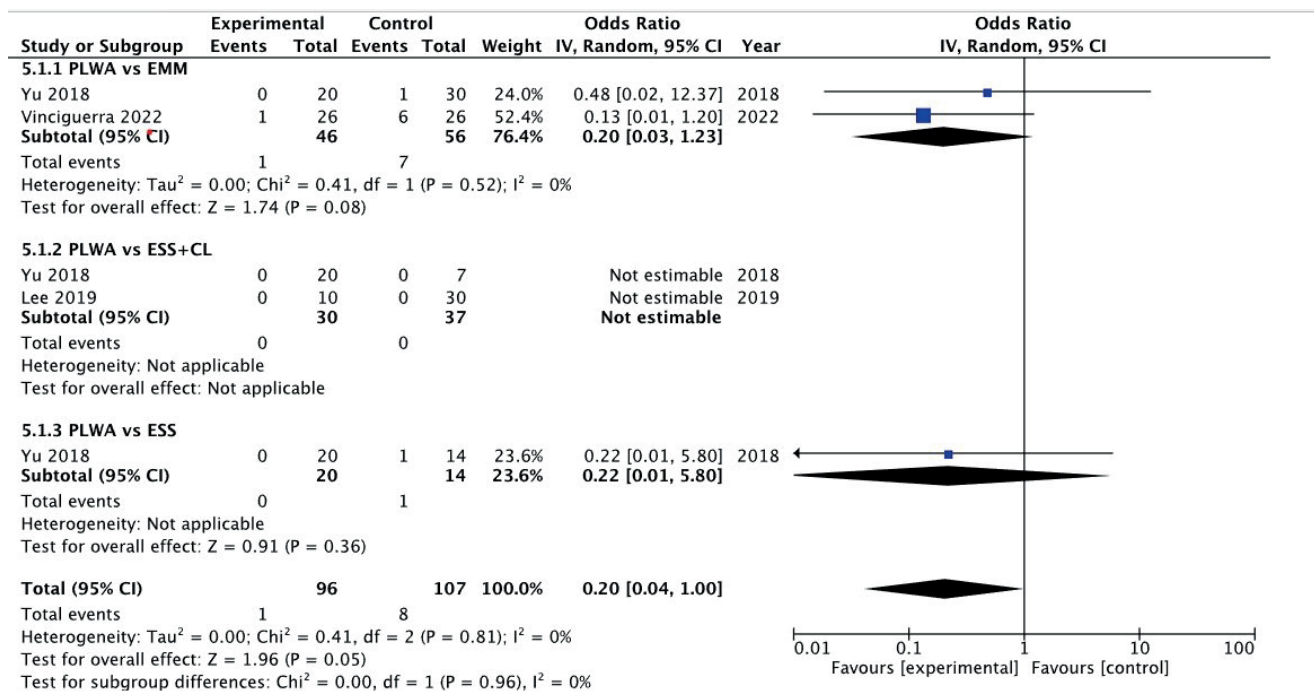


Figure 8. Comparison of the PLWA and conventional surgery on epistaxis/infection requiring intervention. Legend: Pre-Lacrimal Window Approach (PLWA), Endoscopic Sinus Surgery (ESS), Endoscopic Medial Maxillectomy (EMM), Caldwell–Luc operation (CL), Confidence Interval (CI).

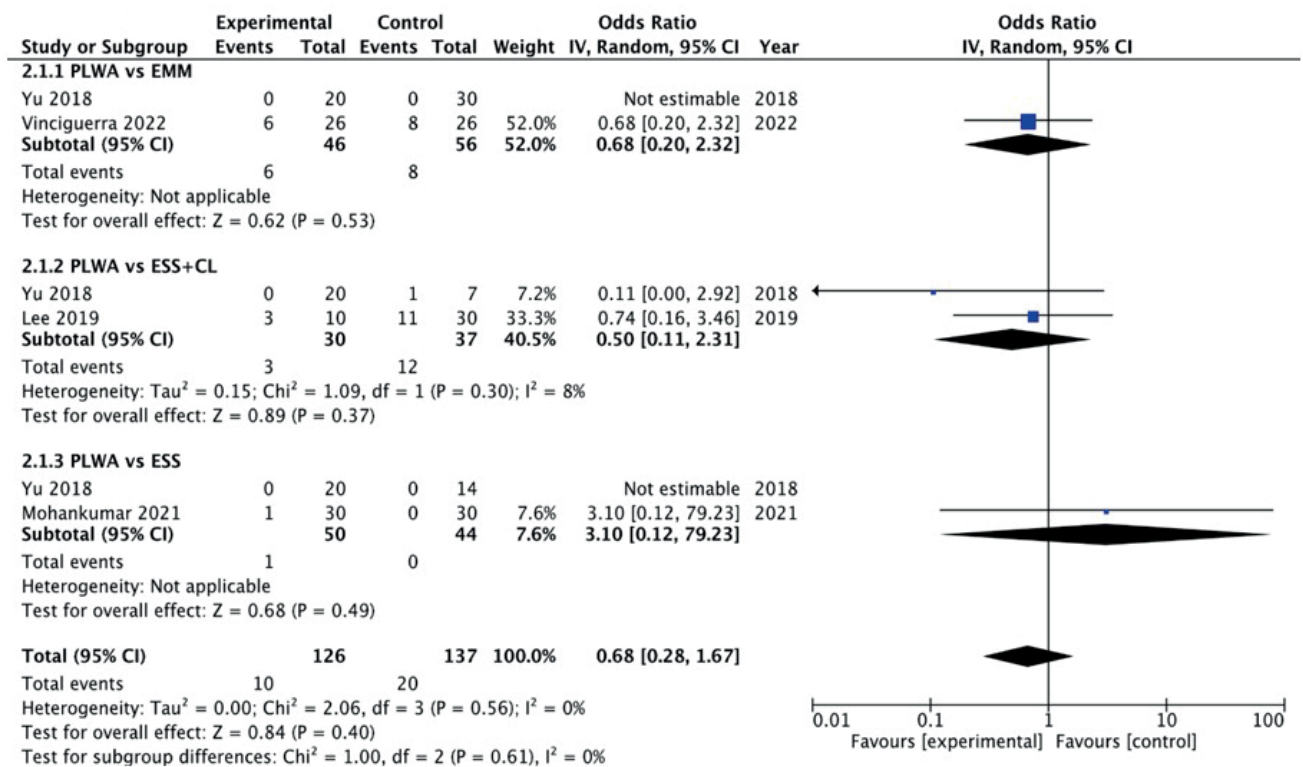


Figure 9. Comparison of the PLWA and conventional surgery on facial or gingival numbness. Legend. Pre-Lacrimal Window Approach (PLWA), Endoscopic Sinus Surgery (ESS), Endoscopic Medial Maxillectomy (EMM), Caldwell–Luc (CL) approach, Confidence Interval (CI).

## Discussion

Over the past few years, there has been a significant increase in the indications for endoscopic sinus surgery, including pathology such as infection, chronic inflammation and sino-nasal tumours<sup>(33,34)</sup>. Since the 1980s, the endoscopic middle meatal maxillary antrostomy has commonly been performed<sup>(14)</sup>. However, this procedure may not allow sufficient access to all walls of the MS to enable their complete removal<sup>(13,14,19)</sup>. In some cases, EMM is often done to provide a better operating field<sup>(30)</sup>. Nevertheless, in EMM, sacrificing the IT and the NLD can lead to functional problems<sup>(9)</sup>. Additionally, technical difficulties persist in reaching particular areas within the MS, especially the anterior and inferior walls<sup>(13)</sup>. Weber et al.<sup>(35)</sup>, Nakamaru et al.<sup>(36)</sup> and Rutherford et al.<sup>(37)</sup>, aimed to preserve the inferior turbinate (IT) or nasolacrimal duct (NLD) when performing an EMM. However, some limitations were encountered despite their efforts. Nakamura et al.<sup>(36)</sup> described a technique that included preserving the NLD during EMM for IP. However, this method faced challenges when dealing with tumors attached to the floor of maxillary sinus with irregular prominences<sup>(36)</sup>. If EMM includes a prelacrimal osteotomy, a comprehensive view of the maxillary sinus can be achieved, similar to that obtained in a PLWA. In cases of extensive lesions or due to anatomical reasons, treating patients exclusively with endoscopic approaches might not always be feasible. In selected cases, a combination of approach-

ches or even an external approach to the MS may be necessary. In 2007 Zhou et al.<sup>(15)</sup>, reported an alternative endoscopic approach to access the MS, known as PLWA. This technique provides wide access to all walls and recesses of the MS without the need for resection of the IT and NLD, thereby allowing the preservation of the nasal anatomy<sup>(9,13)</sup>. The surgical treatment MS pathology by PLWA has been shown to be a safe and an effective technique in the recent years<sup>(12,19,30)</sup>, however, not all patients are candidates for this approach. The feasibility of the PLWA depends on the presence of the PLR and sufficient medial wall width<sup>(38)</sup>. According to Simmen et al.<sup>(17)</sup>, before considering the feasibility of performing a PLWA, it is essential to assess the distance between the lacrimal system and the anterior maxillary wall. If the distance is insufficient, carrying out a PLWA to access the maxillary sinus becomes unfeasible without temporarily displacing or, in some cases, even resecting the nasolacrimal duct<sup>(17)</sup>. Navarro et al.<sup>(39,40)</sup> reported that the prevalence of a PLR was 41.9% and 30.9% in cadaveric specimens and in CT images, respectively. Chen et al.<sup>(41)</sup> showed a percentage of 82.5% of a PLR in Asian patients. So, due to the significant individual variability in the anatomy of PLR, a thorough examination of the preoperative CT scan is essential to help prevent surgical morbidity<sup>(17,41)</sup>. Thus, in the case of an absent PLR and when the distance between the anterior wall of the maxilla and the anterior border of the lacrimal duct is less than 3mm (type 1 Simmen classifica-

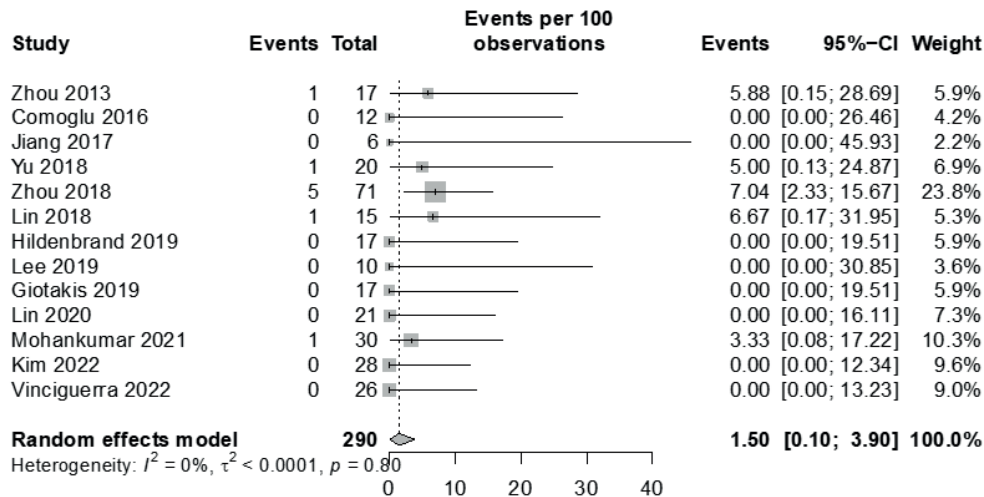


Figure 10. Incidence rates of recurrence of the pathology approached by PLWA. Legend. Pre-Lacrimal Window Approach (PLWA), Confidence Interval (CI).

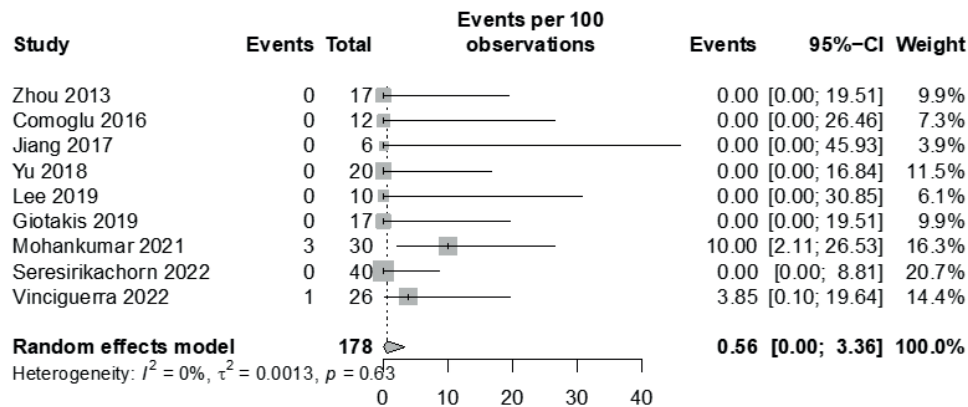


Figure 11. Incidence rates of recurrence of epiphora after PLWA. Legend. Pre-Lacrimal Window Approach (PLWA), Confidence Interval (CI).

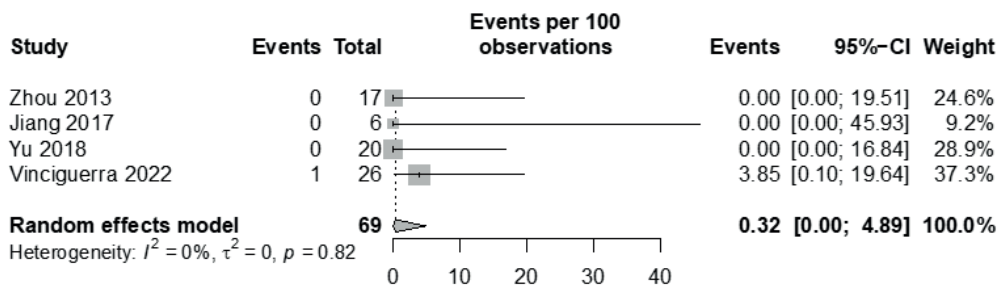


Figure 12. Incidence rates of recurrence of dry nose after PLWA. Legend. Pre-Lacrimal Window Approach (PLWA), Confidence Interval (CI).

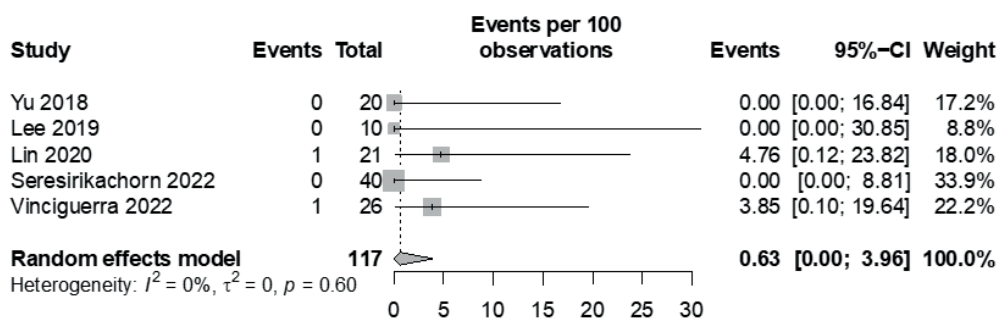


Figure 13. Incidence rates of recurrence of epistaxis/infection requiring intervention after PLWA. Legend. Pre-Lacrimal Window Approach (PLWA), Confidence Interval (CI).

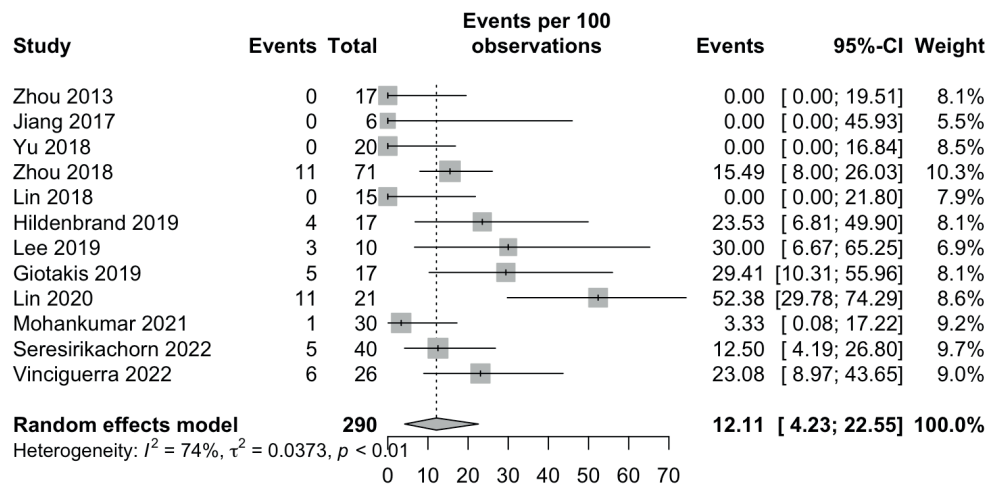


Figure 14. Incidence rates of recurrence of facial or gingival numbness after PLWA. Legend: Pre-Lacrimal Window Approach (PLWA), Confidence Interval (CI).

tion)<sup>(17)</sup>, an alternative to PLWA should be considered. We propose a pre- and post-lacrimal approach as a viable alternative, especially when a type I Simmen PLWA is present. Nonetheless, the type I approach may not necessarily result in a more difficult procedure, as the removal of bone will promptly grant access to the anterior sinus wall.

Recent studies have reported gender-specific differences in the feasibility of a PLWA<sup>(42)</sup>. Andrianakis et al.<sup>(42)</sup> reported a greater distance (1.5 mm (95% CI 0.8–2.2) between the lacrimal system and the anterior maxillary wall in males compared to females. Consequently, females may potentially face an increased risk of intra- and post-operative morbidity due to problems caused by surgery during a PLWA<sup>(42)</sup>.

When performing the PLWA, the choice of incision, whether horizontal or vertical, can impact visibility and effect mucosal flap repositioning. In our experience, a horizontal incision is considered superior for accessing the MS, despite the current lack of literature supporting this. This approach can be particularly beneficial when adjunctive procedures are required, such as maxillary sinusotomy or extended maxillary sinusotomy according to the necessity for access. It's crucial, however, to acknowledge the current lack of evidence supporting its superiority over a vertical incision. The decision on which incision should consider the patient's condition, anatomical factors, and the surgeon's experience with the technique.

The size of the surgical window depends on the origin of the specific pathology, such as inverted papilloma or antrochoanal polyp<sup>(17, 43)</sup>. This approach allows for a customized window size tailored to the individual patient's anatomical considerations<sup>(17, 43)</sup>. By adjusting the window size based on the patient's specific pathology, surgeons can optimize their approach for a more precise and effective treatment. Initiating the procedure with a more limited window size provides a strategic starting point,

with the flexibility to expand the window as necessary during the surgery, ensuring an adaptable and optimal surgical outcome<sup>(17, 43)</sup>.

Throughout the procedure, trauma, and subsequent bleeding from the terminal branches of the lateral nasal artery may compromise visibility. Therefore, the surgeon should carefully cauterise these structures to optimize the surgical field. Even though angled endoscopes can be used, we emphasise that the entire procedure can be performed using a zero-degree endoscope. Based on the author's experience, this approach provides a straight view and effective control over MS pathology. Furthermore, it has the potential to save time on instrumentation, which is an advantage.

Antibiotic therapy, analgesia, nasal corticosteroid spray, and nasal irrigation with a 0.9% saline solution are commonly prescribed after the PLWA<sup>(16, 25)</sup>. We recommend employing absorbable nasal packing, such as NasoPore® or similar materials, to address any potential bleeding in the postoperative period, as there is no significant risk of hemorrhage according to the literature. Vinciguerra et al.<sup>(32)</sup> reported a significant reduction in postoperative pain following PLWA compared to EMM, both during the hospital stay and at the 30-day follow-up. Notably, 76.9% of patients in the PLWA group achieved complete pain control without the need for additional analgesics after hospital discharge, in contrast to the 23.1% observed in the EMM group<sup>(32)</sup>. Furthermore, unlike external approaches such as the CL, the PLWA is performed via a transnasal method, which preserves the periosteum in the canine fossa area<sup>(28)</sup>. The significance of this preservation is highlighted by its role as a primary barrier against the infiltration of MS disease into the skin of the cheek<sup>(28)</sup>. Additionally, the PLWA has no impact on cosmesis and the preservation of the medial maxillary wall, achieved by returning the flap, allows for rapid remucosalization, thereby reducing

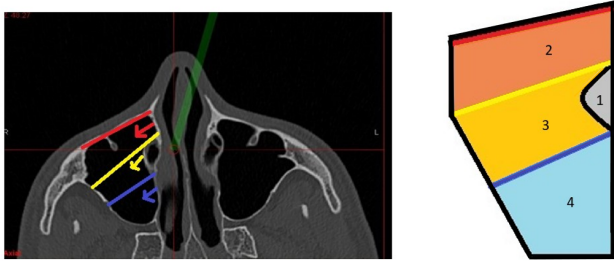


Figure 15. Comparative assessment: visual scope and pathological control efficacy of ENLWD, PLFA and PLWA. A) CT scan, B) Axial visualization of the maxillary sinus and respective approaches in a picturized figure. Legend: The lines without arrow represent: 1 – Nasolacrimal Duct, 2 – PLWA in red, 3 – PLFA in yellow, 4 – ELNWD in blue. The lines with arrows in respective colors represent the area that each technique can offer in terms of visualization of the maxillary sinus and control of pathology (2,3,4).

nasal symptoms<sup>(31, 32)</sup>. Despite this, a noticeable crust typically persists on the incision for at least one month postoperatively after the PLWA.

During the follow-up after PLWA, the MS cannot be thoroughly inspected through endoscopes. To address this issue, the use of a wide middle meatal antrostomy can significantly improve the monitoring of the MS during the post-operative period<sup>(13, 25)</sup>. Nevertheless, it is crucial to recognize that certain pathologies, specifically those affecting the anterior and inferior walls, cannot be adequately surveyed through endoscopy alone<sup>(13, 14)</sup>. This limitation highlights the importance of complementary imaging techniques to comprehensively evaluate the MS<sup>(16, 25)</sup>. Therefore, a comprehensive approach that integrates both endoscopy and imaging is crucial to ensure a thorough and accurate assessment of the post-operative condition after performing a PLWA. We believe that by following these recommendations, post-operative challenges that relate to access and visualization after PLWA may be minimized, thus facilitating post-operative surveillance. The duration of surveillance is also crucial, particularly in cases involving conditions such as inverted papillomas, which may recur after several years<sup>(44)</sup>. Therefore, long follow-up periods may be necessary in certain instances to detect late recurrences<sup>(44)</sup>. In cases of pathology localized in the lateral portion, alveolar recess, and anterior wall of the sinus, the PLWA is recommended<sup>(17)</sup>. Alternatively, for pathology on the posterior or posterior-lateral wall or roof of the MS, an endoscopic maxillary mega-antrostomy (EMMA) proves to be a more suitable surgical intervention<sup>(17, 45)</sup>. In the EMMA, the posterior half of the inferior turbinate is excised, and the antrostomy is extended to the floor of the nose, creating a markedly enlarged opening<sup>(46)</sup>. EMM or Medial Maxillectomy can also offer a complete view on the maxillary sinus, when it includes a pre-lacrimal osteotomy, although, according to our data, more morbidity is associated

with these two techniques when compared to PLWA.

In addition to the PLWA, in the literature there are descriptions of approaches that are conceptionally related to PLWA: Endoscopic nasal lateral wall dissection (ENLWD) and the prelacrimal fossa approach (PLFA). To enhance their differences, we have compiled a comprehensive comparison of the technical aspects of these techniques in Table 4<sup>(15, 16, 25)</sup>. Endoscopic inspection and efficacy of removal for each approach are graphically represented in Figure 15.

Most of the studies included in the current meta-analysis were retrospective cohorts. Nevertheless, we acknowledge the potential for bias that might arise from the selected methodologies. Funnel plot analyses were carried out to evaluate publication bias. Regarding the recurrence outcome, the funnel plot showed no signs of asymmetry. However, given the limited number of studies suitable for meta-analysis, we were unable to perform an accurate assessment of publication bias for the remaining outcomes.

The present meta-analysis shows a significant reduction in the recurrence rate of MS pathologies following PLWA when compared to conventional surgery (ESS, EMM, CL).

We acknowledge concern regarding the inclusion of various pathologies in our meta-analysis, which may potentially introduce confounding factors into our results. In the context of assessing recurrence based on surgical approaches, we compiled data from six studies<sup>(10-12, 24, 28, 32)</sup>. Two<sup>(11, 28)</sup> of them encompassed a range of heterogeneous pathologies, including antrochoanal polyps, while the remaining four<sup>(10, 12, 24, 32)</sup> studies specifically focused on inverted papilloma, which exhibit notably distinct clinical behaviors. Nevertheless, we adopted this approach due to limitations in the available data, as separate analyses for each pathology were often unfeasible due to the limited number of accessible studies. Furthermore, we are aware that, despite their clinical differences, there are common aspects related to treatment and surgical approaches that provide valuable insights into the main aspects of our investigation.

Yu et al.<sup>(12)</sup> reported that patients who had PLWA primarily because their tumor was present on the antero-inferior or infero-lateral wall, or because the lesion had multiple attachment sites in the MS. Six additional studies<sup>(11, 23, 26, 28, 30, 32)</sup> provided data on the specific subsites of involvement and attachment sites for the analyzed lesions, as presented in Table 2. However, not all studies provided this level of information, which is a limitation of the current literature. We strongly recommend that future research focusing on the PLWA clearly delineate these subsites to enhance result reliability.

The postoperative morbidities such as facial or gingival numbness, dry nose, epiphora and epistaxis or infection that requires intervention were not significantly different between procedures. However, the number of studies evaluating postoperative morbidity between the procedures was substantially low and

Table 3. Risk of bias of the included studies, the Newcastle - Ottawa scale.

Study	Year	Study Type	Selection	Comparability	Outcome	Total
Zhou et al. <sup>(16)</sup>	2013	Retrospective cohort	★★★★	-	★★★	7
Comoglu et al. <sup>(23)</sup>	2016	Retrospective cohort	★★★	-	★★	5
Jiang et al. <sup>(24)</sup>	2017	Retrospective cohort	★★★	-	★★★	6
Yu et al. <sup>(12)</sup>	2018	Retrospective cohort	★★	★★	★★★	7
Zhou et al. <sup>(25)</sup>	2018	Retrospective cohort	★★★★	-	★★★	7
Lin et al. <sup>(26)</sup>	2018	Retrospective cohort	★★★★	-	★★★	7
Hildenbrand et al. <sup>(27)</sup>	2019	Retrospective cohort	★★	★★	★★★	7
Lee et al. <sup>(28)</sup>	2019	Retrospective cohort	★★	★★	★★★	7
Giotakis et al. <sup>(29)</sup>	2019	Retrospective cohort	★★★	-	★★★	6
Lin et al. <sup>(30)</sup>	2020	Retrospective cohort	★★★	-	★★★	6
Mohankumar et al. <sup>(11)</sup>	2021	Prospective cohort	★★★★	★★	★★★	9
Seresirikachorn et al. <sup>(31)</sup>	2022	Retrospective cohort	★★★	-	★★★	6
Kim et al. <sup>(10)</sup>	2022	Retrospective cohort	★★★★	★★	★★★	9
Vinciguerra et al. <sup>(32)</sup>	2022	Retrospective cohort	★★★	★★	★★★	8

Table 4. Comparative analysis of surgical approaches- ENLWD, PLFA, PLWA.

Procedures	ENLWD	PLFA	PLWA
Approach	Transnasal	Transnasal	Transnasal
Access Point	Lateral nasal wall	Prelacrimal fosa	Prelacrimal recess
Extent of access	Smaller access point	Small access point	Larger access point
Bone alteration	Minimal bone work	Minimal to no significant bone work	Bone removal
Surgical goals	Address specific maxillary sinus issues with minimal alteration to surrounding anatomy	Access maxillary sinus while preserving nasal anatomy	Comprehensive maxillary sinus access in complex cases with an extended View

Legend: Endoscopic Nasal Lateral Wall Dissection (ENLWD), Prelacrimal Fossa Approach (PLFA), Prelacrimal Window Approach (PLWA).

they had a small sample size. Therefore, the interpretation of surgical complications should be approached with caution. Overall, heterogeneity was low between PLWA and conventional approaches groups, except with regards to epiphora. In this case, subgroup analysis also showed statistically significant heterogeneity among the two groups. It's probable that if the studies had been conducted with more uniform patient groups, the heterogeneity in the epiphora outcome would have been reduced. In terms of crusting, this is mostly when sutures are used, otherwise very little crusting is seen, in the authors' experience. We observed that various studies employed different methods to assess the incidence of dry nose <sup>(12, 16, 24, 32)</sup>, which makes it challenging to establish a single standardized criterion for reporting dry nose as an outcome. To improve future research, we recommend establishing clear assessment criteria to reach a consensus within the medical community. In our review, the incidence of facial or gingival numbness was 12.11% after the PLWA, although there was high heterogeneity.

Among the 12 studies <sup>(11, 12, 16, 24-32)</sup> that reported this outcome, 8 <sup>(11, 25, 27-32)</sup> identified cases of numbness. Of those, 5 <sup>(25, 27, 28, 30, 31)</sup> provided information on whether the numbness duration was temporary or permanent. In the 5 mentioned studies, which included a total of 34 cases of numbness in 159 patients who underwent the PLWA, 25 of the cases were temporary, and 9 cases were permanent. Out of the 25 temporary cases, 13 resolved within a three-month period, while 11 cases resolved within a maximum of six months. The authors did not specify a particular time frame for the resolution of the remaining case. Due to the presence of the superior medial alveolar nerve within the mucosa of the anterior maxillary sinus wall, bone drilling and soft tissue resection may lead to these symptoms <sup>(27, 47)</sup>. Additionally, considering the proximity of the anterior superior alveolar nerve (ASAN) to the shoulder of the inferior turbinate, it is crucial to consider the distance between the two structures before performing the PLWA to prevent postoperative hypoesthesia <sup>(48)</sup>. Therefore, an individual preoperative CT assessment of

the course of the ASAN should be conducted <sup>(48)</sup>.

The possibility of preserving the nasolacrimal duct and the inferior turbinate in the PLWA <sup>(13)</sup> may have led to a significantly low incidence of epiphora (0.56%), dry nose (0.32%) and epistaxis or infection requiring intervention (0.63%) in our review. When referring to the four cases of epiphora observed following the PLWA <sup>(11,32)</sup>, it is important to recognize that the studies in our analysis did not provide data regarding the duration of epiphora nor the need for intervention.

This systematic review and meta-analysis have some limitations. First, the absence of clinical randomized controlled trials (RCTs) to complement the observational studies included in this review remains a notable limitation, thereby reducing the quality of the evidence presented. Second, the small sample size and the variability in follow-up times between articles may also influence the accuracy of the results. Moreover, we acknowledge that the limited data from studies remains a significant constraint. Despite these limitations, this systematic review provides valuable insights into the efficacy of the PLWA in the treatment of various MS pathology, demonstrating its promising role in achieving improved surgical outcomes with lower morbidity. Future research should focus on conducting well designed studies to further validate the efficacy and safety of the PLWA.

## Conclusion

A range of MS pathology can be effectively treated using the PLWA, as it has been shown to result in a lower recurrence rate compared to conventional surgery. The PLWA is a promising technique that provides improved access to the anterior and inferior walls of the MS while reducing morbidity and minimizing surgical complications.

## Acknowledgements

The authors would like to thank Professor Nicholas Jones for his contribution in grammar and scientific revision.

## Authorship contribution

ASM: search, data collection, data analysis, drafting the article, and final approval. JP: search, data collection, data analysis, drafting the article, and final approval. FA: revising the article, and final approval. HDB: revising the article, and final approval. DS: revising the article and final approval.

## Conflict of interest

The authors declare no conflicts of interest.

## Funding

The authors declared no external funding for this research.

## References

- Whyte A, Boeddinghaus R. The maxillary sinus: physiology, development and imaging anatomy. *Dentomaxillofac Radiol*. 2019;48(8):20190205.
- Standring S. *Gray's Anatomy E-Book: Gray's Anatomy E-Book*: Elsevier Health Sciences; 2015.
- Pérez-Sayáns M, Suárez Peñaranda JM, Quintanilla JAS, et al. Clinicopathological features of 214 maxillary sinus pathologies. A ten-year single-centre retrospective clinical study. *Head Face Med*. 2020;16(1):24.
- Datta RK, Viswanatha B, Shree Harsha M. Caldwell Luc surgery: revisited. *Indian J Otolaryngol Head Neck Surg*. 2016;68(1):90-3.
- Low WK. Complications of the Caldwell-Luc operation and how to avoid them. *Aust N Z J Surg*. 1995;65(8):582-4.
- Nakayama T, Tsunemi Y, Kuboki A, et al. Prelacrimal approach vs conventional surgery for inverted papilloma in the maxillary sinus. *Head Neck*. 2020;42(11):3218-25.
- Gadad RD, Saxena V, Rangarajan H. Caldwell Luc in the era of endoscopic approach for maxillary sinus. *J Dentist Def Sect*. 2022;16(2):171-3.
- Hosemann W, Scotti O, Bentzien S. Evaluation of telescopes and forceps for endoscopic transnasal surgery on the maxillary sinus. *Am J Rhinol*. 2003;17(5):311-6.
- Weber RK, Hosemann W. Comprehensive review on endonasal endoscopic sinus surgery. *GMS Curr Top Otorhinolaryngol Head Neck Surg*. 2015;14:Doc08.
- Kim JY, Kim SH, Jang P, et al. Inverted papilloma of the maxillary sinus: a recurrence analysis according to surgical approaches. *J Clin Med*. 2022;11(11).
- Mohankumar V, Kannan DS, Narendrakumar V, Kuppuswamy S, Baby AN. A Comparative study between endoscopic prelacrimal approach and middle meatal antrostomy for maxillary sinus pathologies. *Indian J Otolaryngol Head Neck Surg*. 2021;74(1):90-5.
- Yu QQ, Guan G, Zhang NK, et al. Intranasal endoscopic prelacrimal recess approach for maxillary sinus inverted papilloma. *Eur Arch Otorhinolaryngol*. 2018;275(9):2297-302.
- Morrissey DK, Wormald PJ, Psaltis AJ. Prelacrimal approach to the maxillary sinus. *Int Forum Allergy Rhinol*. 2016;6(2):214-8.
- Kennedy DW, Adappa ND. Endoscopic maxillary antrostomy: not just a simple procedure. *Laryngoscope*. 2011;121(10):2142-5.
- Zhou B, Han DM, Cui SJ, et al. [Endoscopic nasal lateral wall dissection approach to maxillary sinus]. *Zhonghua Er Bi Yan Hou Tou Jing Wai Ke Za Zhi*. 2007;42(10):743-8.
- Zhou B, Han DM, Cui SJ, Huang Q, Wang CS. Intranasal endoscopic prelacrimal recess approach to maxillary sinus. *Chin Med J (Engl)*. 2013;126(7):1276-80.
- Simmen D, Veerasigamani N, Briner HR, Jones N, Schuknecht B. Anterior maxillary wall and lacrimal duct relationship - CT analysis for prelacrimal access to the maxillary sinus. *Rhinology*. 2017;55(2):170-4.
- Robey A, O'Brien EK, Leopold DA. Assessing current technical limitations in the small-hole endoscopic approach to the maxillary sinus. *Am J Rhinol Allergy*. 2010;24(5):396-401.
- Kim DH, Kim SW, Son SA, Jung J, Kim SH, Hwang SH. Effectiveness of the endoscopic prelacrimal recess approach for maxillary sinus inverted papilloma removal: a systematic review and meta-analysis. *Am J Rhinol Allergy*. 2022;36(3):378-85.
- Moher D, Liberati A, Tetzlaff J, Altman DG, Group P. Preferred reporting items for systematic reviews and meta-analyses: the PRISMA statement. *PLoS Med*. 2009;6(7):e1000097.
- Schardt C, Adams MB, Owens T, Keitz S, Fontelo P. Utilization of the PICO framework to improve searching PubMed for clinical questions. *BMC Med Inform Decis Mak*. 2007;7:16.
- Stang A. Critical evaluation of the Newcastle-Ottawa scale for the assessment of the quality of nonrandomized studies in meta-analyses. *Eur J Epidemiol*. 2010;25(9):603-5.
- Comoglu S, Celik M, Enver N, Sen C, Polat B, Deger K. Transnasal prelacrimal recess approach for recurrent antrchoanal polyp. *J Craniofac Surg*. 2016;27(4):1025-7.
- Jiang XD, Dong QZ, Li SL, Huang TQ, Zhang NK. Endoscopic surgery of a sinonasal

- inverted papilloma: Surgical strategy, follow-up, and recurrence rate. *Am J Rhinol Allergy*. 2017;31(1):51-5.
25. Zhou B, Huang Q, Sun J, et al. Resection of inverted papilloma of the maxillary sinus via a prelacrimal recess approach: a multicenter retrospective analysis of surgical efficacy. *Am J Rhinol Allergy*. 2018;32(6):518-25.
26. Lin YT, Lin CF, Yeh TH. Application of the endoscopic prelacrimal recess approach to the maxillary sinus in unilateral maxillary diseases. *Int Forum Allergy Rhinol*. 2018;8(4):530-6.
27. Hildenbrand T, Weber R, Mertens J, Stuck BA, Hoch S, Giotakis E. Surgery of inverted papilloma of the maxillary sinus via trans-lacrimal approach-long-term outcome and literature review. *J Clin Med*. 2019;8(11).
28. Lee JJ, Ahmad Z AM, Kim D, et al. Comparison between endoscopic prelacrimal medial maxillectomy and Caldwell-Luc approach for benign maxillary sinus tumors. *Clin Exp Otorhinolaryngol*. 2019;12(3):287-93.
29. Giotakis EI, Mertens J, Kotrotsos IN, Gudner C, Weber RK. Inverted papilloma of the maxillary sinus: surgical treatment via the endoscopic endonasal pre-lacrimal approach. *B-ENT*. 2019 15(4):325-31.
30. Lin YH, Chen WC. Clinical outcome of endonasal endoscopic prelacrimal approach in managing different maxillary pathologies. *Peer J*. 2020;8:e8331.
31. Seresirikachorn K, Kondo M, Png LH, Kalish L, Campbell R, Alvarado R. Prelacrimal approach to maxillary sinus pathology. *Am J Rhinol Allergy*. 2022;37:194589242211448.
32. Vinciguerra A, Bécaud J, Saroul N, et al. Surgical morbidity of endoscopic medial maxillectomy and endoscopic pre-lacrimal recess approach: a comparative study. *Int Forum Allergy Rhinol*. 2023 Jun;13(6):1051-1054.
33. Luong A, Marple BF. Sinus surgery: indications and techniques. *Clin Rev Allergy Immunol*. 2006;30(3):217-22.
34. Tajudeen BA, Kennedy DW. Thirty years of endoscopic sinus surgery: what have we learned? *World J Otorhinolaryngol Head Neck Surg*. 2017;3(2):115-21.
35. Weber RK, Werner JA, Hildenbrand T. Endonasal endoscopic medial maxillectomy with preservation of the inferior turbinate. *Am J Rhinol Allergy*. 2010;24(6):132-5.
36. Nakamaru Y, Furuta Y, Takagi D, Oridate N, Fukuda S. Preservation of the nasolacrimal duct during endoscopic medial maxillectomy for sinonasal inverted papilloma. *Rhinology*. 2010;48(4):452-6.
37. Rutherford KD, Brown SM. Endoscopic resection of maxillary sinus inverted papillomas with inferior turbinate preservation. *Otolaryngol Head Neck Surg*. 2010;142(5):760-2.
38. Yaylacı A, Alparslan B. Anterior maxillary wall and lacrimal duct relationship in pediatric patients - CT analysis for the feasibility of the prelacrimal recess approach. *Auris Nasus Larynx*. 2022;49(4):618-24.
39. Navarro PeL, Machado AJ, Crespo AN. Assessment of the lacrimal recess of the maxillary sinus on computed tomography scans. *Eur J Radiol*. 2013;82(5):802-5.
40. Navarro PeL, Machado Júnior AJ, Crespo AN. Evaluation of the lacrimal recess of the maxillary sinus: an anatomical study. *Braz J Otorhinolaryngol*. 2013;79(1):35-8.
41. Chen Z, Wang Q, Wang P. Prevalence of the prelacrimal recess in maxillary sinus and its medial bony wall dimensions. *Eur Arch Otorhinolaryngol*. 2021;278(4):1099-105.
42. Andrianakis A, Moser U, Wolf A, et al. Gender-specific differences in feasibility of pre-lacrimal window approach. *Sci Rep*. 2021;11(1):7791.
43. Simmen D, Jones N. Manual of endoscopic sinus and skull base surgery. Second edition. ed. Stuttgart; Thieme; 2014.
44. Yu S, Grose E, Lee DJ, Wu V, Pellarin M, Lee JM. Evaluation of inverted papilloma recurrence rates and factors associated recurrence after endoscopic surgical resection: a retrospective review. *J Otolaryngol Head Neck Surg*. 2023;52(1):34.
45. Ashman A, Psaltis AJ, Wormald PJ, Tan NC. Extended endoscopic approaches to the maxillary sinus. *J Laryngol Otol*. 2020;134(6):473-80.
46. Cho DY, Hwang PH. Results of endoscopic maxillary mega-antrostomy in recalcitrant maxillary sinusitis. *Am J Rhinol*. 2008;22(6):658-62.
47. Kasahara N, Morita W, Tanaka R, Hayashi T, Kenmotsu S, Ohshima H. The relationships of the maxillary sinus with the superior alveolar nerves and vessels as demonstrated by cone-beam CT combined with  $\mu$ -CT and histological analyses. *Anat Rec (Hoboken)*. 2016;299(5):669-78.
48. Machado A, Briner HR, Schuknecht B, Simmen D. Assessment of the anterior superior alveolar nerve and its impact on surgery of the lateral nasal wall. *Rhinology*. 2021;59(5):475-80

**André Sousa-Machado**  
**Department of Otolaryngology**  
**Centro Hospitalar Universitário de**  
**Santo António**  
**Porto**  
**Portugal**

**Tel: +35-19 3906 9577**  
**E-mail:**  
**sousamachado.andre@gmail.com**