

# Histological comparison of nasal polyposis in black African, Chinese and Caucasian patients\*

J.S. Lacroix<sup>1</sup>, C.G. Zheng<sup>2</sup>, S.H. Goytom<sup>3</sup>, B. Landis<sup>1</sup>, I. Szalay-Quinodoz<sup>4</sup>, D.D. Malis<sup>1</sup>

<sup>1</sup> Rhinology and Olfactology Unit, ENT Department, University Hospital, Geneva, Switzerland

<sup>2</sup> ENT Department, EENT Hospital, Shanghai Medical University, Shanghai, PR China

<sup>3</sup> ENT Department, Mekane-Hiwot Hospital, Asmara, Eritrea

<sup>4</sup> Department of Pathology, University Hospital, Geneva, Switzerland

## SUMMARY

*We have compared the histological aspects of nasal mucosa biopsies (n = 130) obtained during bilateral polypectomy and ethmoidectomy performed in black African (n=50), Chinese (n=30) and Caucasian patients (n=50) suffering from bilateral nasal polyposis (NP). The three groups of patients were matched for age and sex. The African and Chinese patients did not receive any medical treatment before endoscopic nasal surgery (ENS). All Caucasian patients were treated with corticosteroid nasal spray (400 mg/day) for 6 months. In the absence of subjective and objective clinical improvement, ENS was performed after antibiotic treatment for 10 days and prednisolone 1 mg/ kg/ day for 5 days.*

*Clinical staging of the NP was graded from I to III (I = polyps limited to the middle meatus, II = polyps extending beyond the middle meatus, and III = polyps occupying the entire nasal cavity).*

*Stage I NP was present in 22% of the Caucasians and 30% of the Chinese. Stage II was found in 58% of the Caucasians, 56 % of the Chinese and 8% of the Africans. Stage III was found in 92% of the Africans, while only 20% of the Caucasians and 14% of the Chinese patients had stage III. The extent of submucosal oedema and number of mast cells were similar for the three groups of patients. A significantly greater number of eosinophils were observed in African polyps. Lymphocytes as well as plasmacytes were rare in African but abundant in polyps from both Chinese and Caucasian. Ulceration of the overlying epithelium of the polyps was observed in 20% of the African and 10% of both Chinese and Caucasians patients. We did not find any significant thickening of the basal membrane.*

*We cannot exclude the possibility that the histological difference observed between African and Chinese polyps is related to the very common use among the Chinese population of topical intranasal treatment according to their traditional medicine practices. Since no major histological difference was found in the nasal mucosa and polyps obtained from the three groups of patients, NP in African, Chinese and Caucasian patients is very probably a similar inflammatory disease in all three ethnic groups.*

*Key words: nasal polyposis, nasal mucosa, inflammation, black African, Chinese, Caucasian, endoscopic nasal surgery*

## INTRODUCTION

Nasal polyposis (NP) is the ultimate manifestation of chronic inflammation of the upper airways mucosa characterized by swellings that occur usually in the middle meatus and ethmoid sinuses and prolapsed into the nasal cavity (Zuckermandl, 1882). This chronic disease seems more frequent in men than in women and may affect 1% to 4% of the general adult popu-

lation in Europe (Hoseman et al., 1994). Despite the fact that nasal polyps have been observed in all racial groups, there are as yet no published reports regarding the incidence of this disease and its histological characteristics in the African and Chinese populations.

One can differentiate simple polyp from bilateral polyposis as well as to what extent chronic inflammation of the ethmoid cells is a pre-polypoidal condition (Hoseman et al., 1994).

The development of nasal polyps is most likely multifactorial. Inflammation of the mucus membrane of the ostiomeatal complex and the ethmoidal sinuses is the most frequent primary step for polyp formation. This inflammation can be related to viral, bacterial or fungal and host interactions followed by the local accumulation of inflammatory mediators (Stierna, 1996).

Histologically, the eosinophilic polyp is the most frequent and accounts for 85% to 90% of all nasal polyps. It is characterized by oedema, goblet cell hyperplasia, thickened basement membrane and eosinophilia. Another histological variety is the fibro inflammatory polyp, which presents chronic inflammation and epithelial metaplasia. Some polyps present severe hyperplasia of the seromucinous glands, but have many features resembling those of the eosinophilic type. Though rare, a polyp with atypical stromal cells exists. Careful interpretation of the histological features is essential to avoid confusion with malignant tumors (Hellquist, 1996).

The surface epithelial membrane of nasal polyps is a classical respiratory epithelium. Polyps, however, exhibit a greater number of goblet cells and areas of metaplastic changes. Areas of desquamation, ulceration and necrosis can be observed. Thick basement membrane and hyalinization can be seen. The presence of inflammatory cells such as eosinophils, neutrophils, lymphocytes, plasmocytes and activated mast cells is a histological feature in most nasal polyps (Stierna, 1996).

The predominant inflammatory cells in NP were found to be eosinophils (Ogawa, 1986; Dellacono et al., 1997). Eosinophils are located mainly in the sub endothelial and perivascular spaces of the polyp (Dellacono et al., 1997). Since eosinophils are present in varying amounts in different diseases associated with nasal polyposis, the classification of polyps as eosinophilic and non-eosinophilic may not be relevant (Rowe-Jones et al., 1997).

The aim of the present study was to compare the histopathological characteristics of nasal polyps obtained from African, Chinese and Caucasian patients in relation to the stage of the disease and the medical treatment given before polypectomy.

## MATERIALS AND METHODS

### *Patients*

**African patients:** fifty consecutive patients aged between 7 and 63 years (mean age 27 years) were included in the study. Five patients were under the age of 10; none of them had cystic fibrosis. There were 24 females and 26 males. They were diagnosed in the outpatient clinic of the Ear, Nose and Throat (ENT) Department of the Mekane-Hiwot Hospital, Asmara, Eritrea.

**Chinese patients:** thirty consecutive patients aged between 8 and 60 (mean age 29 years) were studied. Three patients were under the age of 10; none of them had cystic fibrosis. There were 13 females and 17 males. They were seen at the outpatient clinic of ENT Department, EENT Hospital, Shanghai Medical University, Shanghai, People's Republic of China.

**Caucasian patients:** fifty consecutive patients aged between 6 and 61 (mean age 28 years) were included in this group. Five patients were under the age of 10; none of them had cystic fibrosis. There were 24 females and 26 males. They were diagnosed at the Rhinology Unit of the ENT Department, University Hospital of Geneva, Switzerland.

### *Experimental procedures*

All experimental procedures were explained and demonstrated in full and all subjects provided informed consent. The study was conducted according to the declaration of Helsinki on biomedical research involving human subjects (Hong Kong amendment 1989). In all groups, the diagnosis was based on the history of symptoms such as chronic nasal obstruction, anosmia, purulent anterior and/or posterior discharge and facial pain for more than 18 months. Anterior rhinoscopy was performed using a 0° endoscope connected to a cold light source (Stortz, Germany). Posterior rhinoscopy was performed with a 90° endoscope. Clinically, none of the patients included in this study had asthma, allergy or any other pre-operative systemic disease.

Nasal polyposis was classified as one of three clinical stages according to Malm (1997) i.e. stage I: polyps confined to the middle meatus, stage II: polyps extending beyond the middle meatus, and stage III: polyps totally occluding the nasal cavity. None of the African or Chinese patients had received antibiotics or corticosteroids. In contrast, all Caucasian patients had received for at least 6 months before ENS a corticosteroid nasal spray (400 mg/day). They were pretreated with trimetoprim-sulfamethoxazol 160 mg and 800 mg, respectively, twice daily for 10 days and prednisolone 1 mg/kg/day for 5 days before ENS.

Polypectomy, partial antero-inferior middle turbinectomy and complete ethmoidectomy were performed under control with a 0° endoscope (Stortz, Germany) in all patients under general anaesthesia.

### *Histological analysis*

The nasal mucosa tissue samples were fixed in 10 % formaldehyde, dehydrated and embedded in paraffin. Five mm sections were cut and stained with hematoxylin-eosin. In addition, 20 polyp samples from each group were stained with toluidine blue to evaluate mast cell infiltration. They were mounted on slides and examined under a Zeiss microscope. All biopsies were randomly numbered and analyzed by ISQ and JSL who did not know the origin of the tissue samples.

Histological analysis of the polyp tissue samples included integrity of epithelium, presence or absence of oedema and degree of inflammation, using a subjective scale graded from 0 to 3, where 0 meant no inflammatory cells and 3 represented abundant inflammatory cells. The predominant inflammatory cell type in relation to the stage of polyposis was also determined.

### *Statistical analysis*

Statistical analysis was performed using one way ANOVA, *p* value < 0.05 was considered as significant.

RESULTS

Clinical staging of nasal polyposis in the Caucasian group was 22% stage I, 58% stage II and 20% stage III. In the group of African patients, none was stage I, 8% were stage II and 92% were stage III. In contrast, 30% of the Chinese patients were stage I, 56% were stage II and 14% were stage III (Figure 1). Comparison of the mean value of the polyposis stage between the three groups of patients studied showed that the Africans had significantly ( $p < 0.001$ ) more severe clinical staging than the Caucasians and Chinese.

Histological analysis of the polyps and the nasal mucosa of their pedicles revealed that the degree of submucosal oedema was similar in the three groups of patients (data not shown). Evaluation of the density of eosinophils in the biopsies studied showed a predominance of this type of inflammatory cell in African ( $p < 0.001$ ) compared to the Chinese and Caucasian patients (Figure 2). This eosinophil predominance in African polyps was observed in polyposis stage II and III. There was no statistical difference regarding the quantity of eosinophils between Chinese and Caucasian polyps for all stages studied. Plasmocytes as well as lymphocytes were rare in African biop-

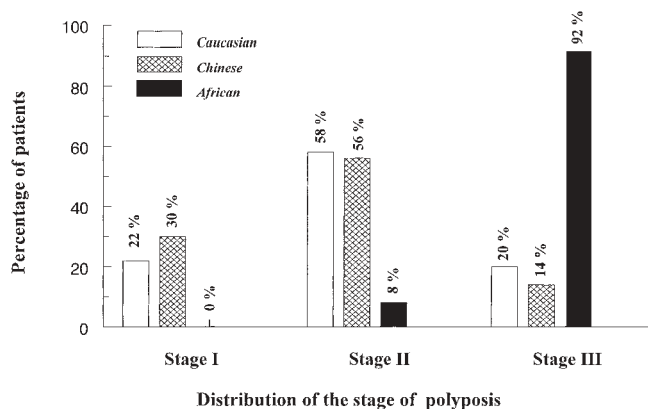


Figure 1. Distribution of patients in relation to the stage of nasal polyposis.

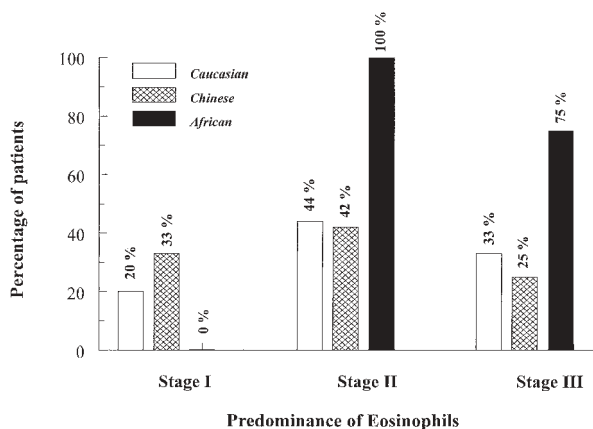


Figure 2. Distribution of patients with eosinophil predominance in relation to the stage of nasal polyposis.

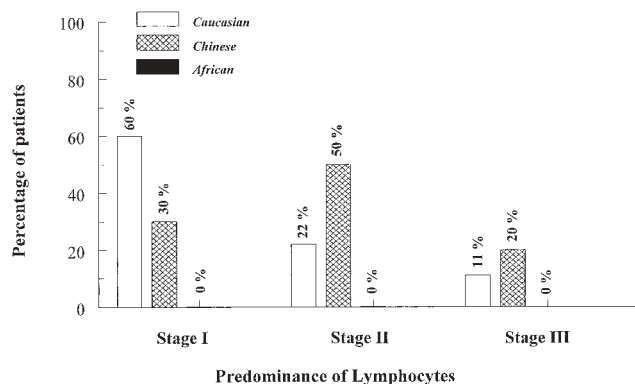


Figure 3. Distribution of patients with plasmocyte predominance in relation to the stage of nasal polyposis.

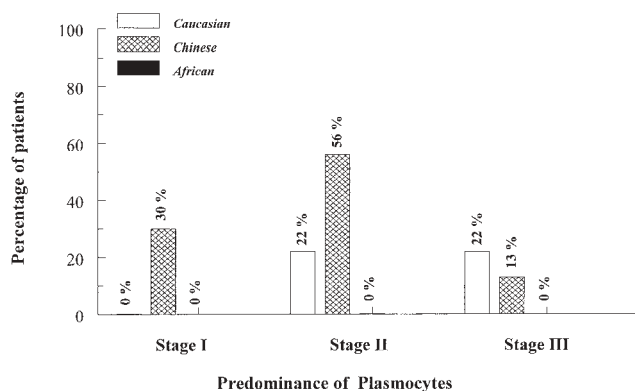


Figure 4. Distribution of patients with lymphocyte predominance in relation to the stage of nasal polyposis.

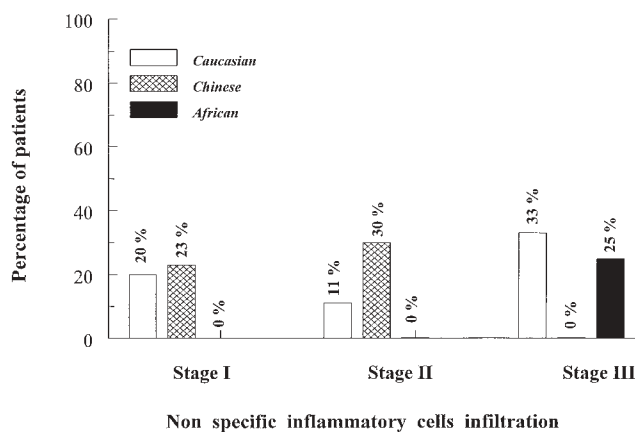


Figure 5. Distribution of patients with non-specific inflammatory cell infiltration in relation to the stage of nasal polyposis.

ses but abundant in both Chinese and Caucasian (Figures 3 and 4). Lymphocytes were predominant in 60 % of European biopsies with stage I polyposis, in 22% of stage II and in 11% of stage III (Figure 4). In Chinese polyps, lymphocytes predominated in 30% of stage I, in 50% of stage II and 20% of stage III

(Figure 4). Plasmocytes were the most frequent inflammatory cells in 22% of the Caucasian patients with stage II and III polyposis (Figure 3). In stage I and II Chinese polyps, the presence of plasmocytes was significantly greater compared to the Caucasian polyps (Figure 3).

Non-specific inflammatory cell infiltration was observed in 20% of the Caucasian stage I polyps and in 23% of the Chinese (Figure 5). These non-specific inflammatory cells were predominant in 11% of the Caucasians and in 30% of the Chinese with stage II. Regarding stage III NP, non-specific inflammatory cells were absent in Chinese but observed in 33% of the Caucasian and 25% of the African polyps (Figure 5).

Toluidine blue staining of 20 nasal mucosa samples from each group showed no significant difference in the number of mast cells infiltrating the polyps (data not shown). Ulceration of the overlying epithelium of the polyps was observed in 20% of the African samples and 10% of both Chinese and Caucasians. We did not find any significant thickening of the basal membrane.

## DISCUSSION

This is the first study to compare the histological aspects of nasal polyps from patients with markedly different geographical and ethnological backgrounds. The main finding of this study is that there is no major histological difference in the nasal polyps obtained from African, Chinese and Caucasian patients. This observation suggests that nasal polyposis could be the same disease entity in the 3 groups studied. The comparison of NP clinical staging between the three populations studied revealed that 92% of the African patients had stage III NP, whereas the Chinese and the Caucasian groups had a similar distribution of patients among the 3 stages of NP. Furthermore, the degree of inflammation was much more severe in Africans compared to the Caucasians and Chinese. African polyps had the highest eosinophil infiltration compared to the other 2 groups. This is most probably due to the lack of medical treatment such as corticosteroid and antibiotic therapy in Eritrea. However, such medical treatment is also lacking in China. The eosinophils density was similar in Chinese and Caucasian polyps. We cannot exclude that the histological difference observed between African and Chinese polyps may be related to the very common use among the Chinese population of topical intranasal treatment according to their traditional medicine practices. In a recent study on patients undergoing polypectomy, Zheng et al. (2000) reported that post-operative daily intranasal application of capsaicin (the pungent principle of red hot pepper), frequently used as a topical intranasal treatment in traditional Chinese medicine, inhibited or significantly reduced the progression or recurrence of nasal polyps when compared to placebo. Some African patients may also have used traditional medicine. However, our African co-author has never seen topical intranasal treatment in Eritrean traditional medicine.

Another surprising observation is the presence of plasmocytes and lymphocytes in Chinese polyps, and to a lesser extent in Caucasian polyps, whereas both types of these inflammatory

cells were rare in African polyps. We do not have a valid explanation for this finding.

Topical steroid treatment is known to reduce the number of lymphocytes in nasal polyp tissue (Kenai et al., 1994). Surprisingly, lymphocytes were present in steroid-treated Caucasian polyps but rare in comparison to other inflammatory cells in steroid-free African polyps.

No significant difference was observed regarding the number of mast cells infiltrating the polyps among the 3 groups studied. This observation is in agreement with a previous study reporting the absence of topical steroid therapy effect on the number of mast cells in nasal polyps (Kenai et al., 1994).

In conclusion, no major histological difference was found in the nasal mucosa and polyps obtained from the three groups of patients, suggesting that NP is very likely a similar inflammatory disease in black African, Chinese and Caucasian patients.

## ACKNOWLEDGEMENTS

This study was supported by the Swiss National Fund for Scientific Research No: 31-056745.99

## REFERENCES

- Hellquist HB (1996) Nasal polyps update. *Histopathology. Allergy Asthma Proc* 17: 237-242.
- Hosemann WG, Grude U, Wagner W (1994) Epidemiology, pathophysiology of nasal polyposis and spectrum of endonasal sinus surgery. *Am J Otolaryngol* 15: 85-98.
- Kanai N, Denburg J, Jordana M, Dolovich J (1994) Nasal polyps inflammation: effect of topical nasal steroid. *Am J Respir Crit Care Med* 150: 1094-1100.
- Malm L (1997) Assessment and staging of nasal polyposis. *Acta Otolaryngol* 117: 465-467.
- Ogawa H (1986) Atopic aspect of eosinophilic nasal polyposis and a possible mechanism of eosinophil accumulation. *Acta Otolaryngol* 430: 12-17.
- Rowe-Jones JM, Trendel-Smith N, Shembekar M, Mackay IS (1997) Polypoid rhinosinusitis in patients with host defence deficiencies: Cellular infiltration and disease severity. *Rhinology* 35: 113-117.
- Stierna PLE (1996) Nasal polyps: relationship to infection and inflammation. *Allergy Asthma Proc* 17: 251-257.
- Zheng CQ, Wang ZM, Lacroix JS (2000) Effect of intranasal treatment with capsaicin on the recurrence of polyps after polypectomy and ethmoidectomy. *Acta Otolaryngol* 120: 62-66.
- Zuckerkindl E (1882) *Normale und pathologische Anatomie der Nasenhöhle und ihrer pneumatish Anhänge*. Vienna: Wilhelm Braumüller.

J.S. Lacroix MD, PhD  
Rhinology and Olfactology Unit  
Department of Otorhinolaryngology  
University Hospital  
CH- 1211 Geneva  
Switzerland

Tel: +41-22-372 8234  
Fax: +41-22-372 8240  
E-mail: silvain.lacroix@hcuge.ch